

Evaluating the Ototoxicity of Aminoglycosides in an Equine Population

Alex True, DVM Candidate Class of 2023 and Dr. Monica Aleman, MVZ Cert., PhD, DACVIM (LAIM & Neurology)

Research Question:

- What effect does the use of aminoglycosides have on the hearing and vestibular systems of neonatal foals and adult horses?

Background:

- Aminoglycosides have been known to cause ototoxic effects in a wide-range of species:
 - Mice/Guinea Pigs (Sullivan et al., 1987)
 - Horses (Dacre et al., 2003)
 - Human neonates (Cooper et al., 2011)
- Aminoglycosides are frequently used in foal neonates, especially for the common condition of sepsis (Bucki et al., 2004)
- Brainstem auditory evoked response (BAER) can be used to assess the hearing capabilities of foal neonates (Aleman et al., 2014)

Methods:

- Vestibular System:** Performed vestibular neurological exam before aminoglycoside was administered and again 7 days after continued daily drug use on neonatal foals, and for the adult horses conducted exam at the end of their treatment
 - Clinical evaluation of vestibular deficit after detecting presence of strabismus, nystagmus, nausea, ataxia, or loss of balance when tight circling or when blindfolded

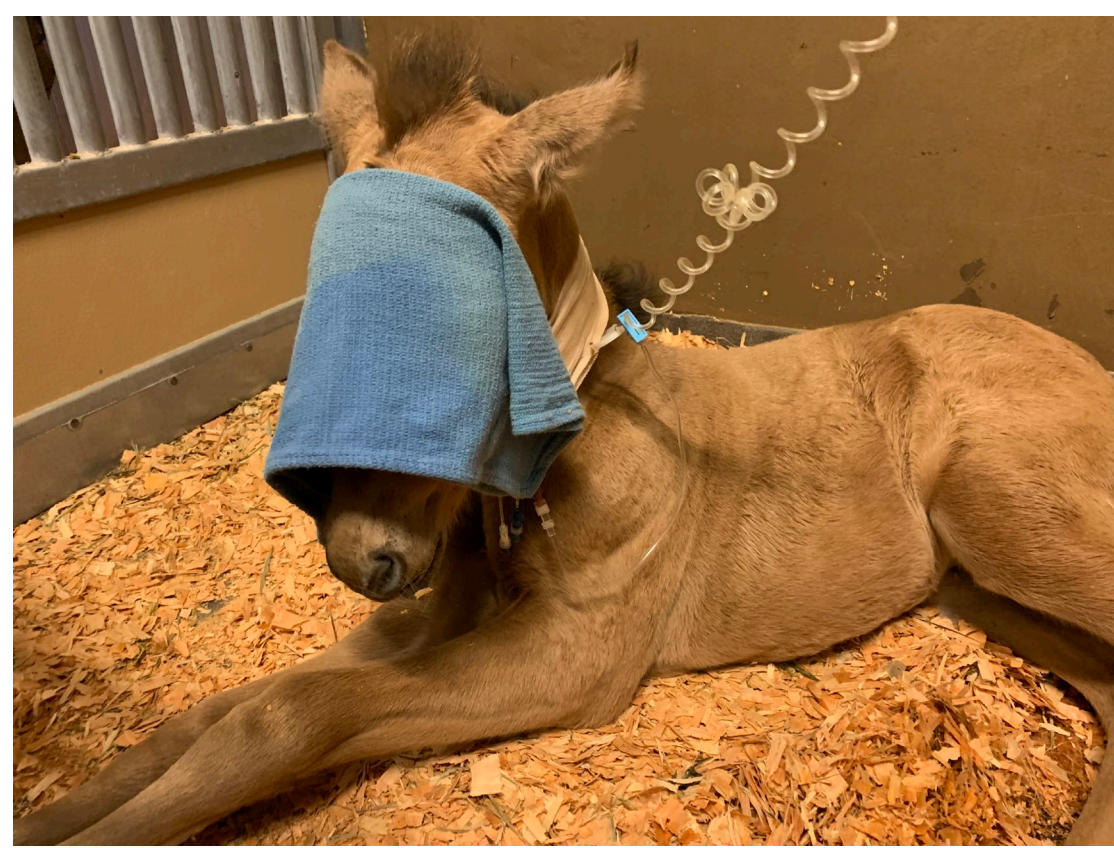

Figure 1. Foal Undergoing Blindfold Test for Vestibular Disease.

Auditory System: Took BAER measurements at 80 dB and 95 dB air conduction (Fig. 2 and 3) and 55 dB bone conduction at the end of the aminoglycoside treatment in the adult horses, and for the neonatal foals performed basic hearing test before and after 7 days of treatment

- Compared latencies and peaks of waves 1, 3, and 5 using unpaired t-tests to adult horse reference ranges
- Bone conduction tests the auditory pathway from the cochlea to the central nervous system

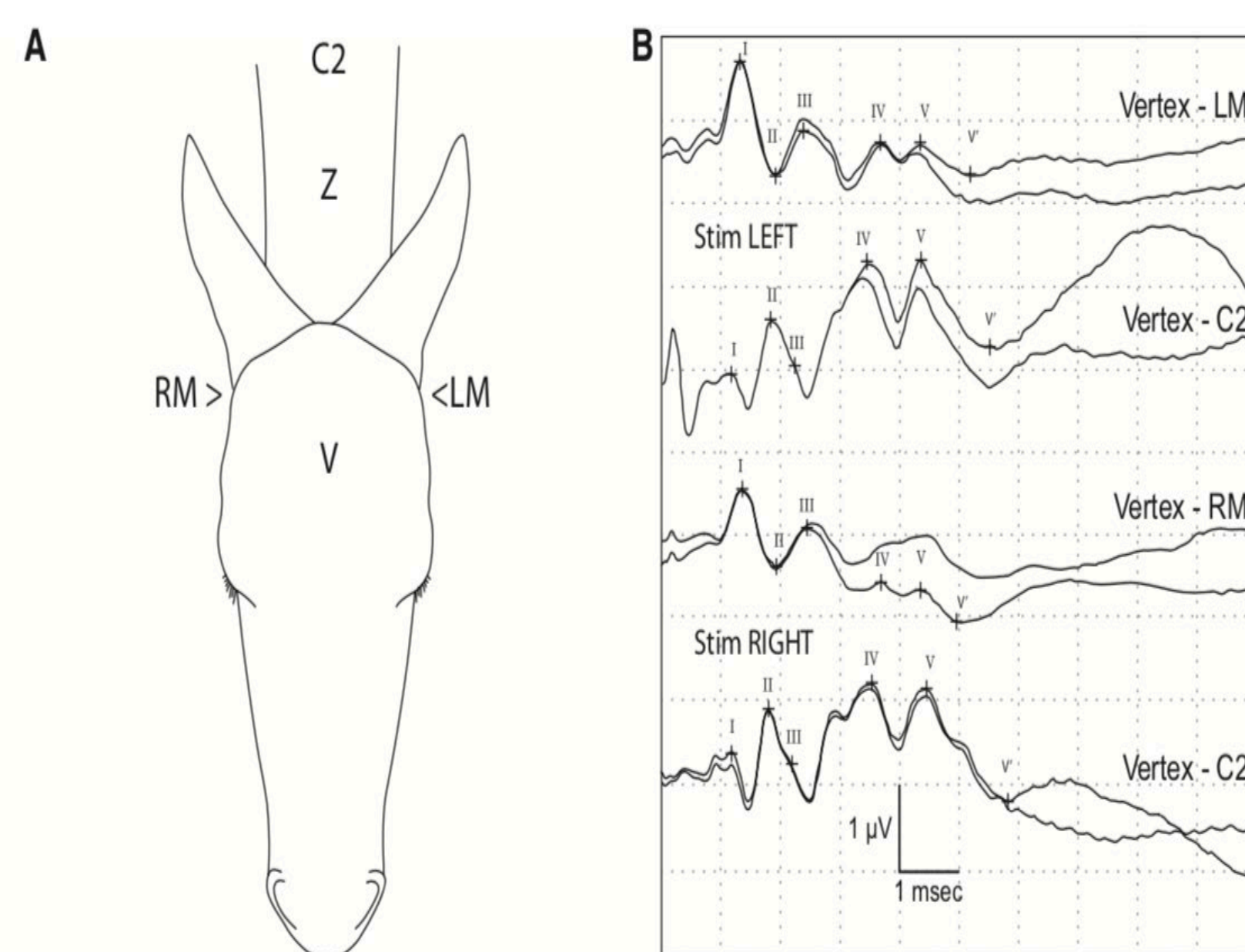


Figure 2. Diagram of Placement of BAER electrodes and Read-out of Potential Curves in a Foal with Normal Hearing for Air conduction (Aleman, et al., 2014). A) Placement of BAER electrodes with V (vertex) in the center of the head, RM (right mastoid) at the base of the right ear, LM (left mastoid) at the base of the left ear, and C2 at the level of C2 on midline. B) Top two curves are left ear and bottom two curves are right ear with each curve having a duplicate. Each of the peaks are labeled and correspond to separate parts of the auditory sensory pathway.

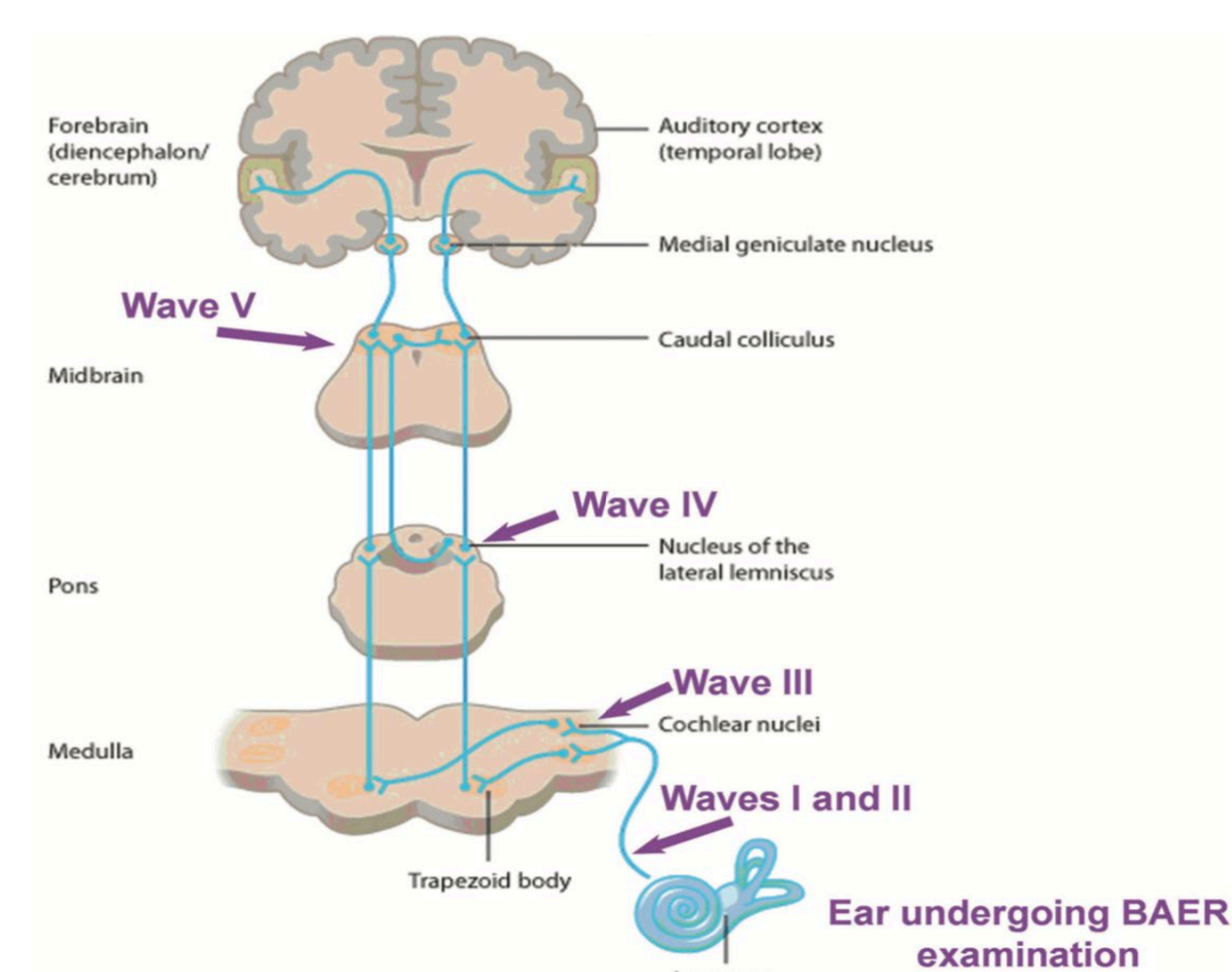


Figure 3. Corresponding Parts of Auditory Sensory Pathway with BAER Waves for Air Conduction (Webb, 2009).

Results – Vestibular System:

- Neonatal Foals:** No change on vestibular exam after aminoglycoside treatment
- Adult Horses:** No vestibular deficits noted following treatment



Figure 4. Foal Undergoing Standing Blindfold Test. Any swaying or incoordination is noted as a vestibular deficit.

Results – Auditory System

- Neonatal Foals:** No complete deafness noted on basic hearing test in neonatal foals
- Adult Horses:** No statistical significance in latencies and peaks between reference and research values (Tables 1 and 2)

80 Decibels (ms)	Research A1	Reference A1	Research C2	Reference C2
Wave 1 Latency	2.15 ± .86	2.21 ± .12	2.32 ± .32	2.11 ± .12
Wave 3 Latency	3.83 ± .58	3.61 ± .34	3.59 ± .38	3.62 ± .34
Wave 5 Latency	5.56 ± .62	5.36 ± .32	5.69 ± .32	5.38 ± .24

Table 1. Average Latencies with 2 Standard Deviations for Waves 1, 3, and 5 at 80dB in Both Research Horses and Reference Values. The research and reference range latencies for all the waves overlap with the standard deviations. The A1 refers to the wave from the mastoid to the vertex, and the C2 refers to the wave from C2 to the vertex.

95 Decibels (ms)	Research A1	Reference A1	Research C2	Reference C2
Wave 1 Latency	2.04 ± .70	2.21 ± .12	2.17 ± .20	2.11 ± .12
Wave 3 Latency	3.86 ± .50	3.61 ± .34	3.66 ± .42	3.62 ± .34
Wave 5 Latency	5.68 ± .38	5.36 ± .32	5.70 ± .34	5.38 ± .24

Table 2. Average Latencies with 2 Standard Deviations for Waves 1, 3, and 5 at 95dB in Both Research Horses and Reference Values. The research and reference range latencies for all the waves overlap with the standard deviations. The A1 refers to the wave from the mastoid to the vertex, and the C2 refers to the wave from C2 to the vertex.

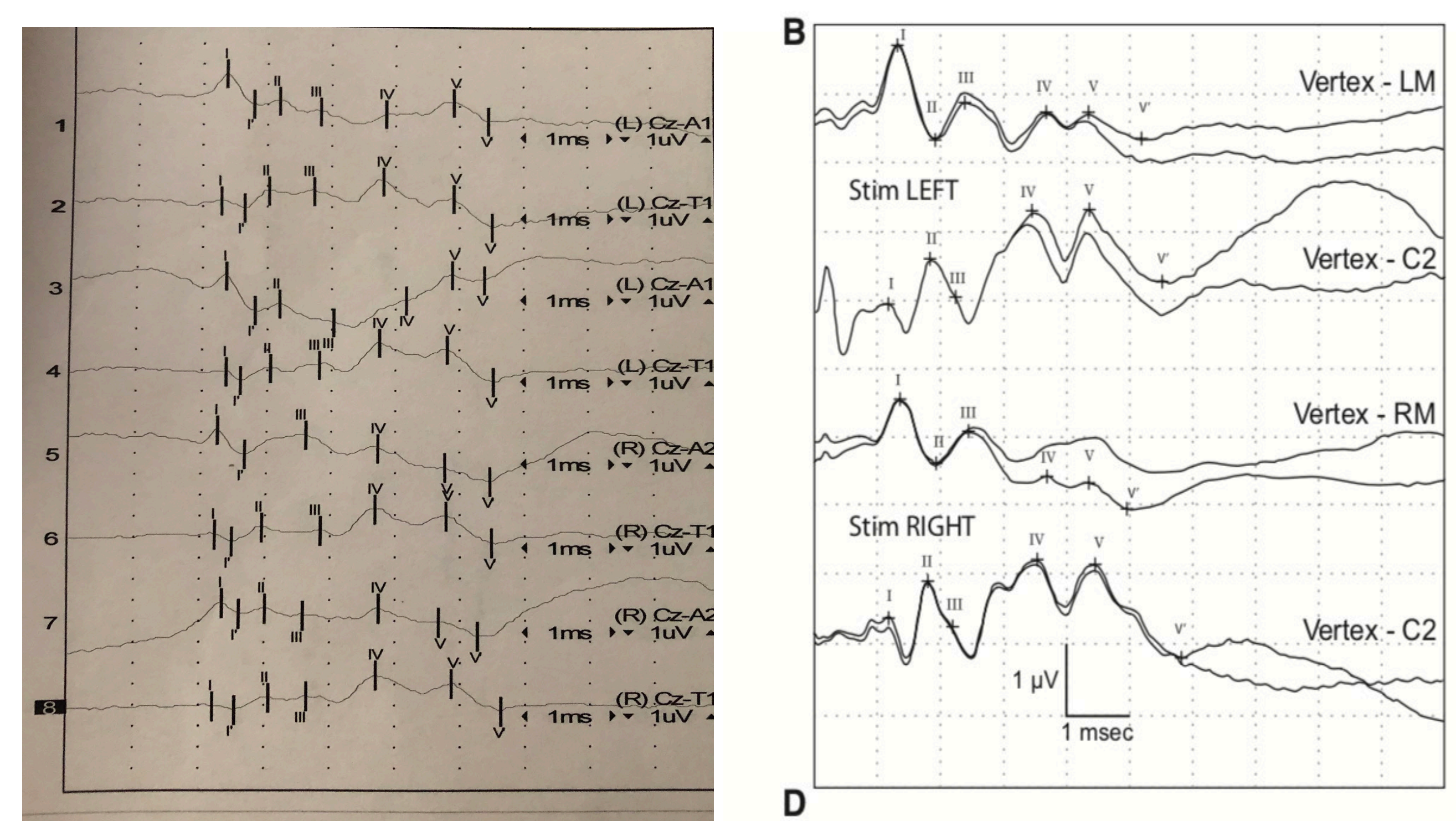


Figure 5. One Experimental BAER Readout Compared to the Reference BAER Readout. Although there is a difference in vertical scale (one dot is one mV on the left and one box is one mV on the right) the experimental waves match the reference waves closely. It is important to note that A1 refers to mastoid, and the reference waves put the two trials together on one graph while the experimental readout separated the two trials.

Conclusions:

- Summary of Significance:** Clinicians should feel assured that at current dosing regimens at the VMTH no significant ototoxic effects were detected
- Future Directions:**
 - Using BAER to test ototoxicity of aminoglycosides in neonatal foals
 - Evaluating whether there is a developmental component to why neonatal humans have ototoxic effects but neonatal horses do not

References and Acknowledgements:

- Aleman, M., Madigan, J. E., Williams, D. C., & Holliday, T. A. (2014). Brainstem Auditory Evoked Responses in an Equine Patient Population. Part II: Foals. *Journal of Veterinary Internal Medicine*, 28(4), 1318–1324.
- Bucki, E. P., Giguere, S., Macpherson, M., & Davis, R. (2004). Pharmacokinetics of Once-Daily Amikacin in Healthy Foals and Therapeutic Drug Monitoring in Hospitalized Equine Neonates. *Journal of Veterinary Internal Medicine*, 18(5), 728–733.
- Dacre, K. J. P., Pirie, S., & Prince, D. P. (2003). Choke, pleuropneumonia and suspected gentamicin vestibulotoxicity in a horse. *Equine Veterinary Education*, 15(1), 27–33.
- Sullivan, M. J., Rarey, K. E., & Conolly, R. B. (1987). Comparative ototoxicity of gentamicin in the guinea pig and two strains of rats. *Hearing Research*, 31(2), 161–167.
- Webb, A. A. (2009). Brainstem auditory evoked response (BAER) testing in animals. *The Canadian Veterinary Journal*, 50(3), 313–318.
- Chelsea Crowe, MA
- Lais Costa, MedVet, MS, PhD, DACVIM, DABVP
- Philip Kass, DVM, MPVM, MS, PhD, Diplomate ACVPM (Epidemiology)
- Isaac Pessah, MS, PhD
- Eileen English
- Clinicians in the Large Animal Clinic at the Veterinary Medical Teaching Hospital at UC Davis
- Financial Support from the STAR Program – Woodmansee endowment