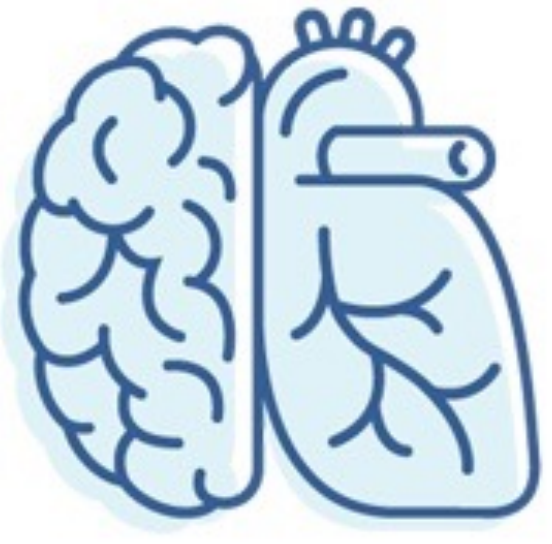

Validation of automated MRI segmentation protocols of neuroanatomical regions of the rhesus macaque brain

Brittany Davis¹, Joey Charbonneau^{2,3}, Erika Raven^{3,4}, Jeffery Bennet^{3,5,6}, Eliza Bliss-Moreau^{3,6}

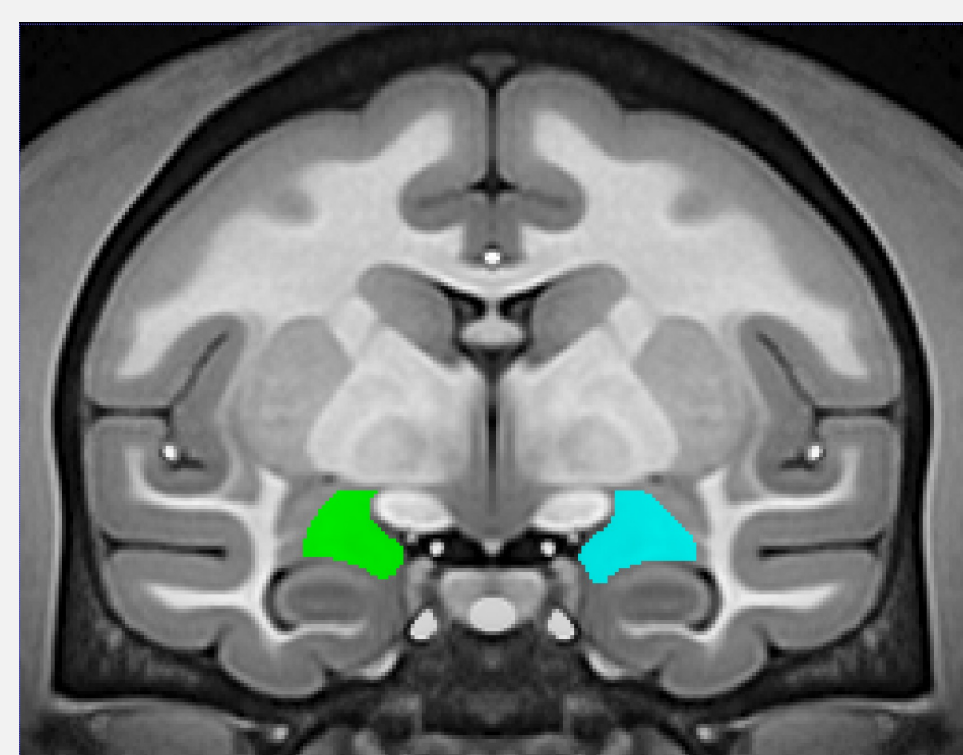
¹School of Veterinary Medicine, University of California Davis, Davis, CA, USA ²Neuroscience Graduate Program, University of California Davis, Davis, CA, USA ³California National Primate Research Center, University of California Davis, Davis, CA, USA ⁴New York University School of Medicine, Department of Radiology, New York, NY, USA ⁵Department of Psychiatry and Behavioral Sciences, University of California Davis, Davis, CA, USA ⁶Department of Psychology, University of California Davis, Davis, CA, USA

Introduction

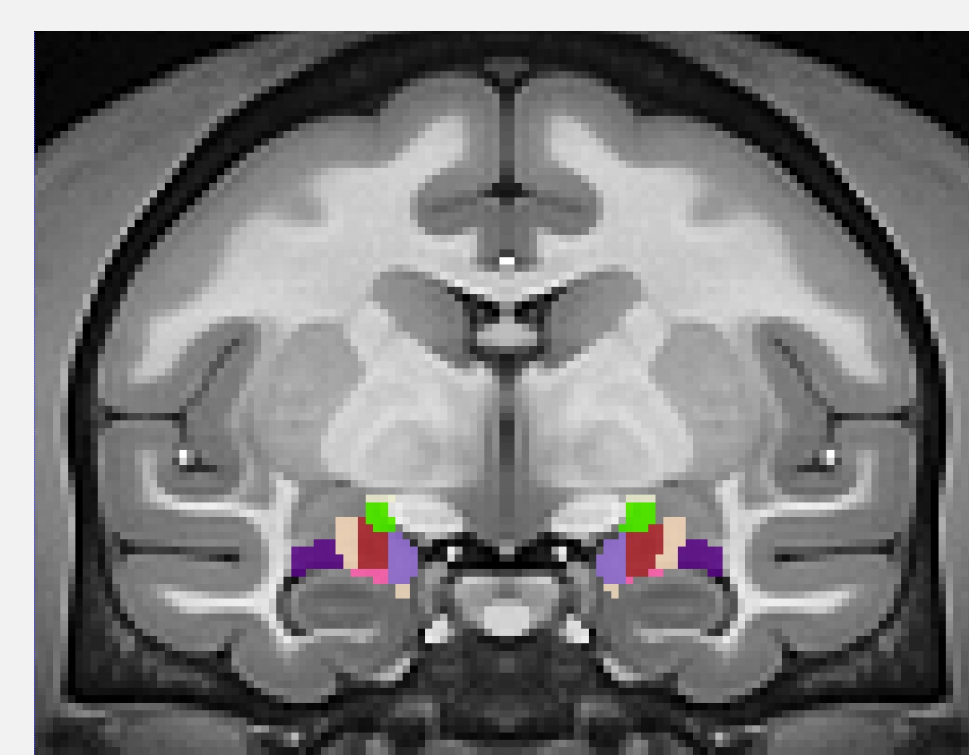
MRI is a valuable neuroimaging tool that allows researchers to obtain anatomical data in live subjects. Historically, **hand segmentation** methods have been used to delineate regions on scans by manually drawing structures on scans. This method is time and labor-intensive. **Automated segmentation** methods utilize specialized software to apply an atlas to a novel subject brain. This approach is efficient and becoming increasingly popular. While the accuracy and reproducibility of these methods has been questioned in human neuroimaging¹⁻², there is scarce evidence validating the performance of the atlases for use in animal models. We chose to compare the performance of these methods on two structures in the rhesus monkey, a widely used animal model of human neurologic disease: the **amygdala** (subcortical) and the **insula** (cortical).

Methods

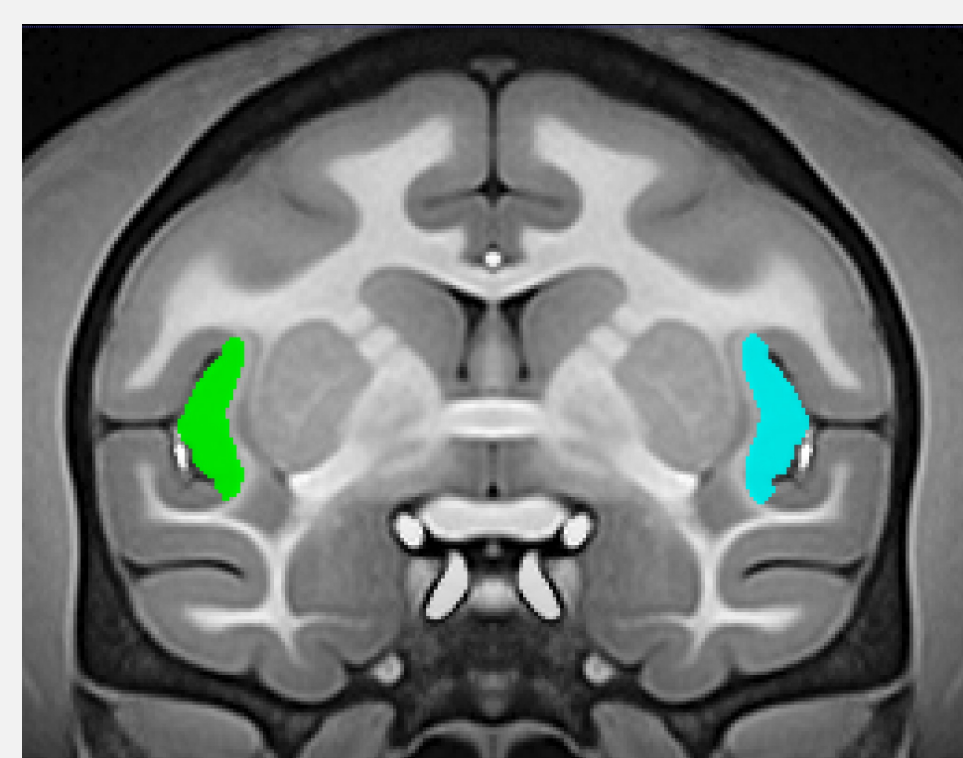
Subjects:
36 rhesus macaques (22 males, 14 females; 1.1-20.3 years old)
Hand segmentation was carried out in **ITK-Snap**³.
Automated segmentation methods used two atlases: **SARM**⁴, which is specific to subcortical structures, and **CHARM**⁵, which is specific to cortical structures. We added together regions of interest from the atlases that most closely approximated the hand-drawn structures.



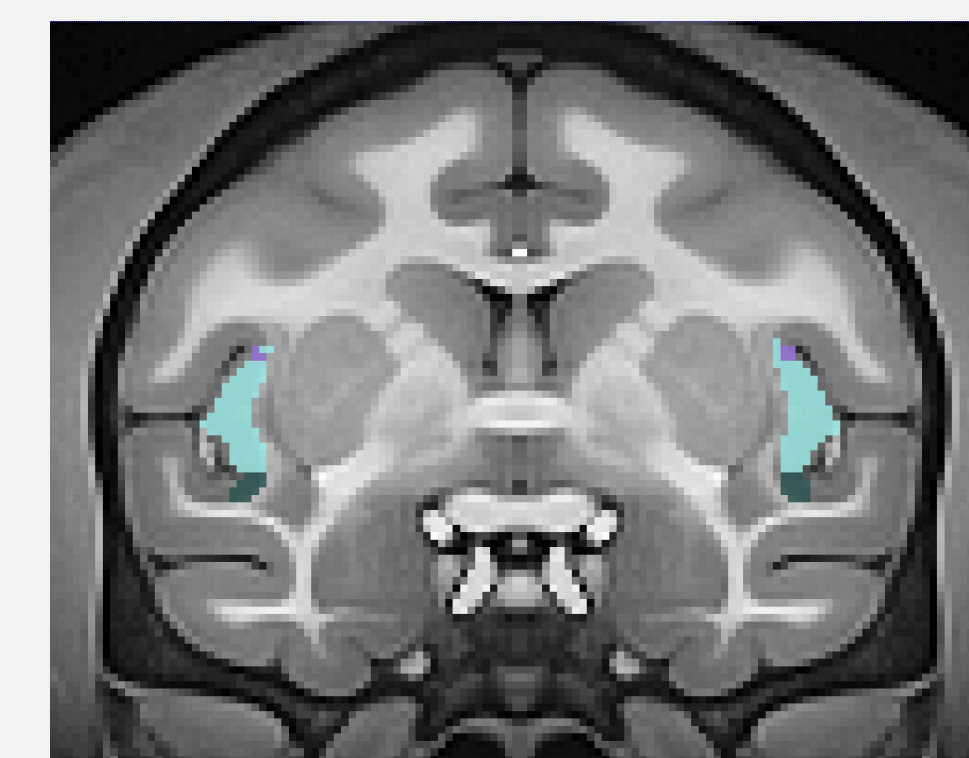Hand-drawn amygdala in NMT v2 brain.



SARM amygdala regions in NMT v2 brain.



Hand-drawn insula in NMT v2 brain.

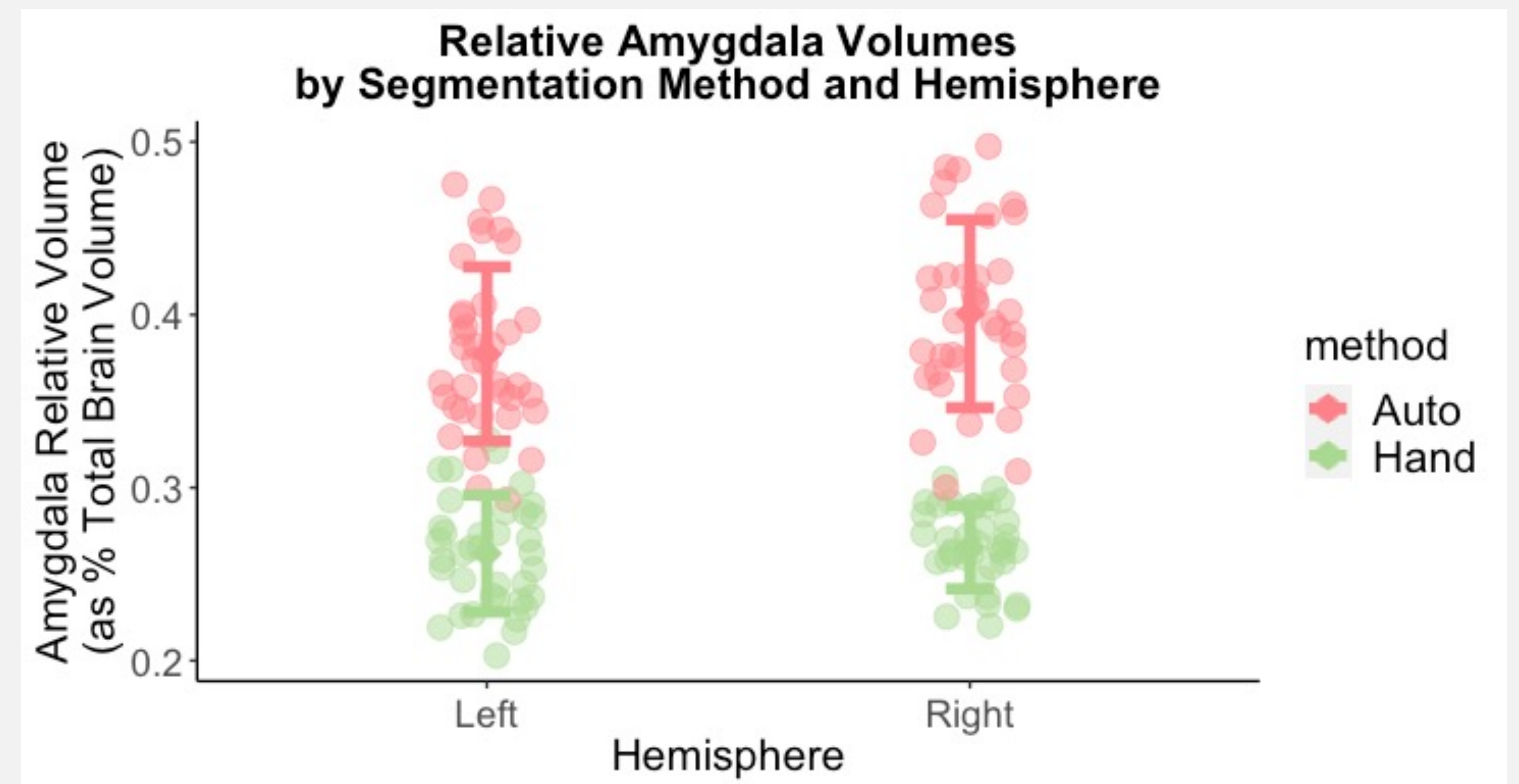


CHARM insula regions in NMT v2 brain.

Discussion

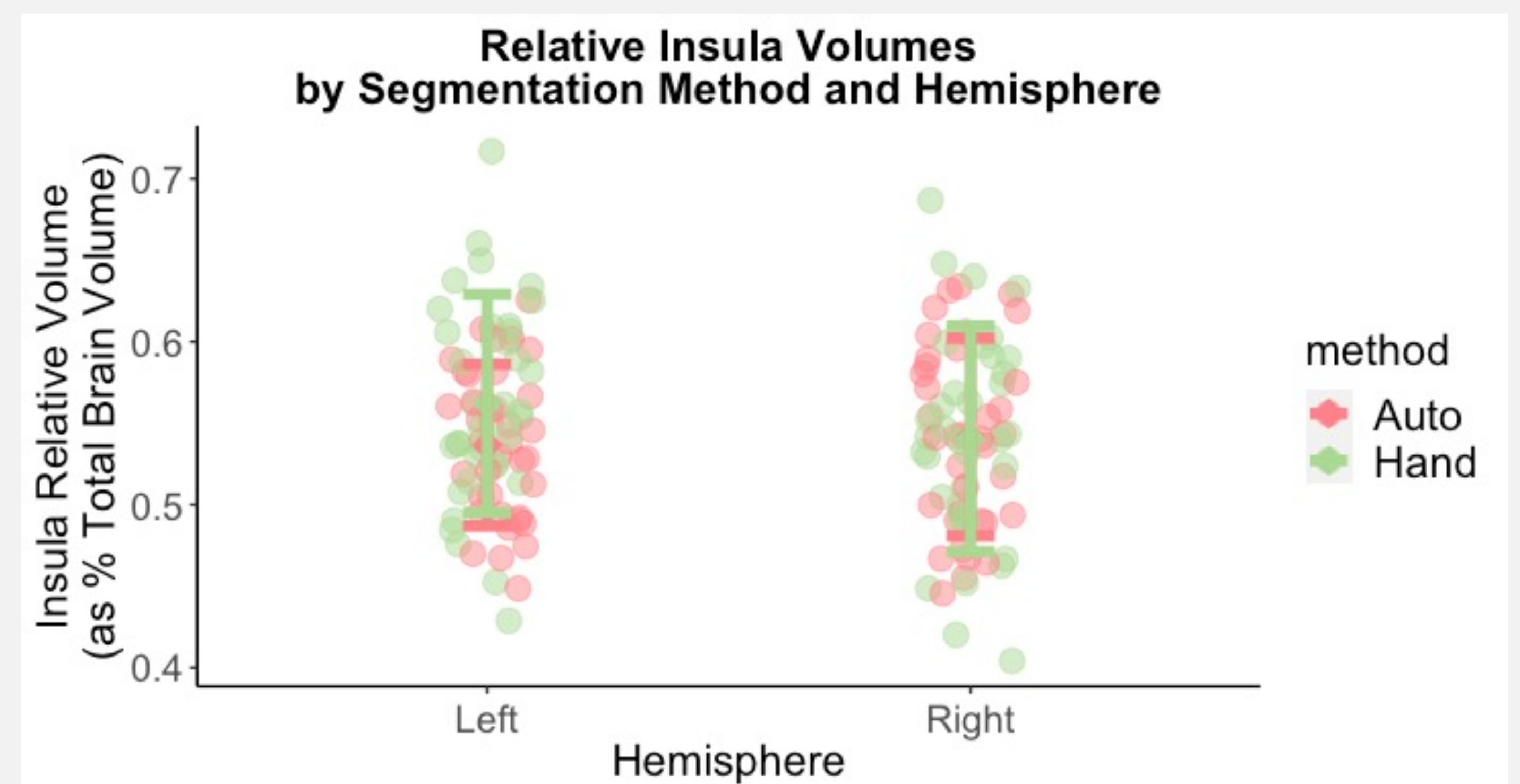
Automated segmentation methods do not produce accurate volumetric data for subcortical structures. Atlas registration to subject brains appears to be a problem in automated methods. **Using automated methods may lead to drawing incorrect conclusions about the volumes of anatomical structures and their relationships to one another.** Future work: compare the performance of hand and automated methods in additional structures.

Results



Correlation between Hand and Auto Segmented Amygdala Volumes:
 $r = -0.06$
 $p = 0.75$

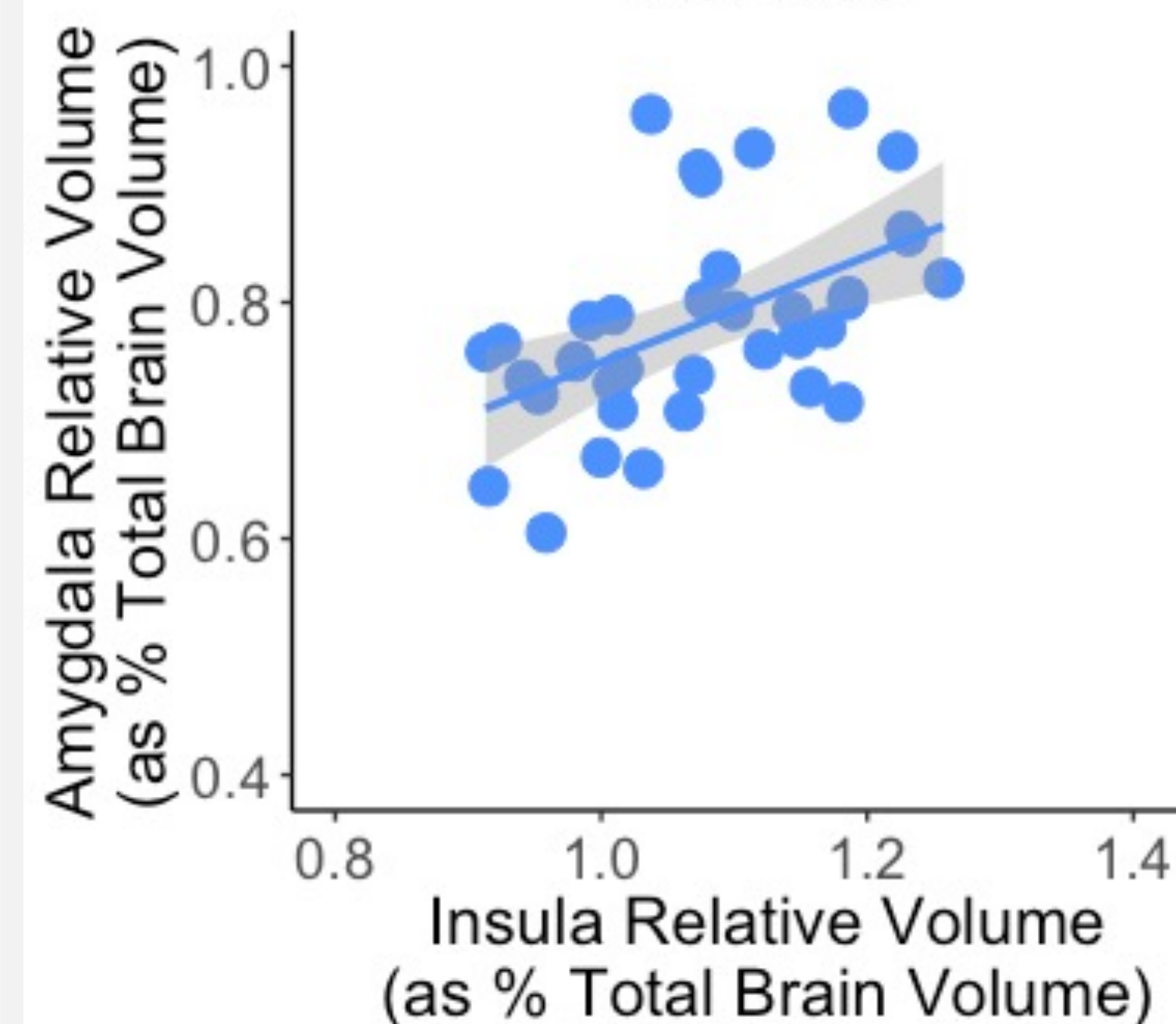
Predictors of Hand Segmented Amygdala:
• Auto Seg Amygdala: not significant ($\chi^2(1) = 0.08, p = 0.77$)
• Age: not significant ($\chi^2(1) = 0.06, p = 0.81$)
• Sex: trend ($\chi^2(1) = 3.25, p = 0.07$)
• Hemisphere: not significant ($\chi^2(1) = 0.58, p = 0.45$)



Correlation between Hand and Auto Segmented Insula Volumes:
 $r = 0.67$
 $p < 0.001$

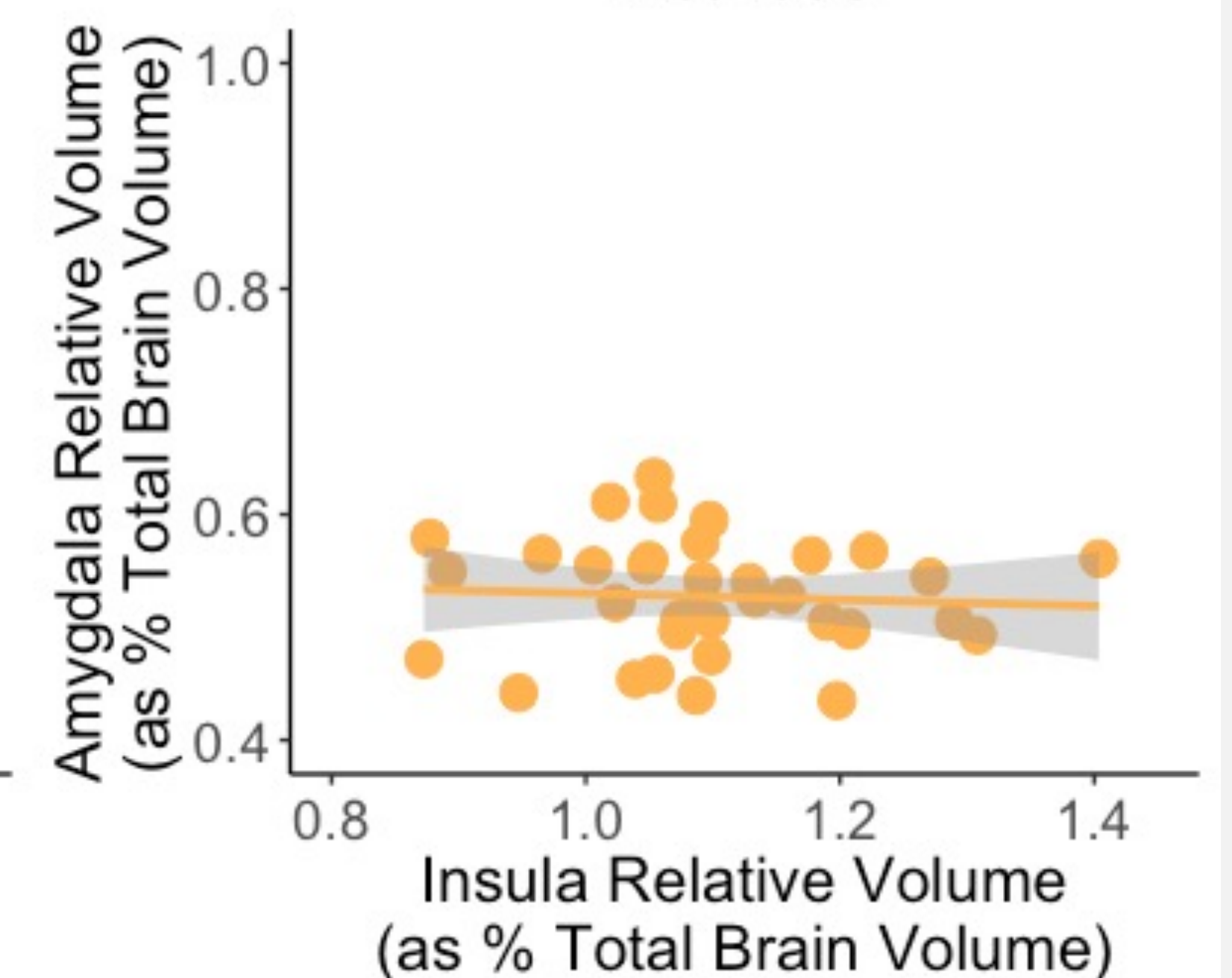
Predictors of Hand Segmented Insula:
• Auto Seg Insula: significant ($\chi^2(1) = 28.8, p < 0.001$)
• Age: significant ($\chi^2(1) = 7.69, p < 0.01$)
• Sex: significant ($\chi^2(1) = 5.82, p = 0.02$)
• Hemisphere: significant ($\chi^2(1) = 18.4, p < 0.001$)

Automated Segmentation Methods



Correlation between Auto amygdala and Auto insula:
 $r = 0.51 (p = 0.002)$

Hand Segmentation Methods



Correlation between Hand amygdala and Hand insula:
 $r = -0.07 (p = 0.70)$

Acknowledgements

Financial support was provided by the STAR Program through a UC Davis School of Veterinary Medicine Endowment Fund.

References

- Botvinik-Nezer, R., Holzmeister, F., Camerer, C. F., Dreber, A., Huber, J., Johannesson, M., Kirchler, M., Iwanir, R., Mumford, J. A., Adcock, R. A., Avesani, P., Baczkowski, B. M., Bajracharya, A., Bakst, L., Ball, S., Barilari, M., Bault, N., Beaton, D., Beitner, J., . . . Schonberg, T. (2020). Variability in the analysis of a single neuroimaging dataset by many teams. *Nature*, 582(7810), 84-88. <https://doi.org/10.1038/s41586-020-2314-9>
- Gomez-Ramirez, J., Quilis-Sancho, J., & Fernandez-Blazquez, M. A. (2021). A Comparative Analysis of MRI Automated Segmentation of Subcortical Brain Volumes in a Large Dataset of Elderly Subjects. *Neuroinformatics*. <https://doi.org/10.1007/s12021-021-09520-z>
- Yushkevich, P. A., Piven, J., Hazlett, H. C., Smith, R. G., Ho, S., Gee, J. C., & Gerig, G. (2006). User-guided 3D active contour segmentation of anatomical structures: Significantly improved efficiency and reliability. *Neuroimage*, 31(3), 1116-1128. <https://doi.org/https://doi.org/10.1016/j.neuroimage.2006.01.015>
- Hartig, R., Glen, D., Jung, B., Logothetis, N. K., Paxinos, G., Garza-Villarreal, E. A., Messinger, A., & Evrard, H. C. (2021). The Subcortical Atlas of the Rhesus Macaque (SARM) for neuroimaging. *Neuroimage*, 235, 117996. <https://doi.org/10.1016/j.neuroimage.2021.117996>
- Jung, B., Taylor, P. A., Seidlitz, J., Sponheim, C., Perkins, P., Ungerleider, L. G., Glen, D., & Messinger, A. (2021). A comprehensive macaque fMRI pipeline and hierarchical atlas. *Neuroimage*, 235, 117997. <https://doi.org/10.1016/j.neuroimage.2021.117997>